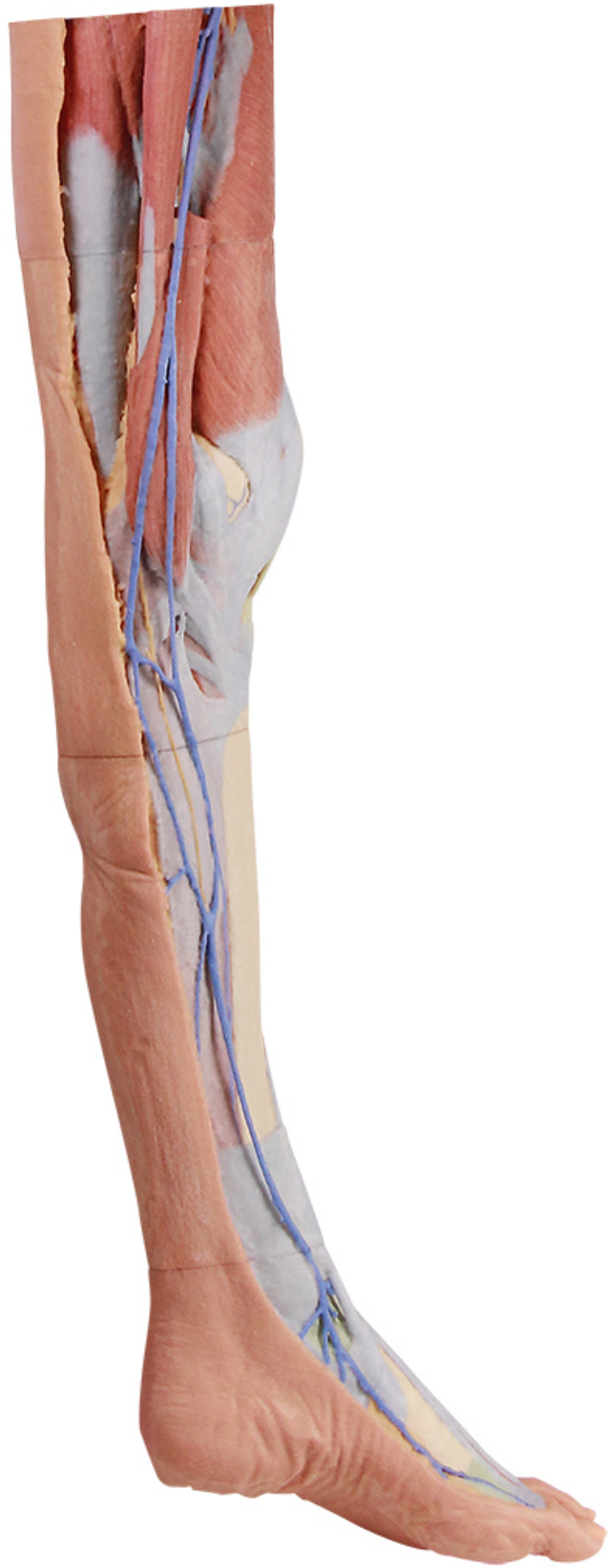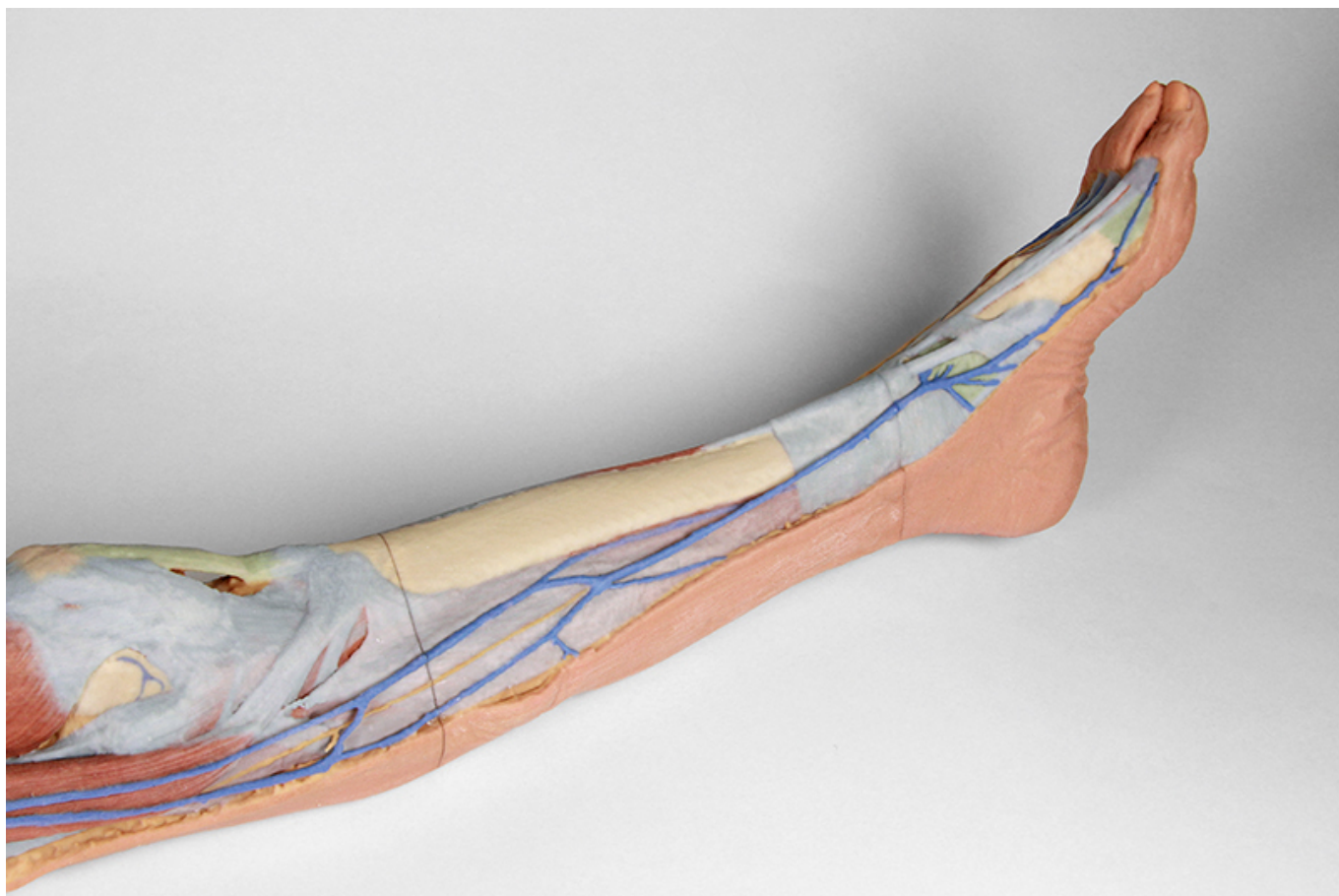




HELAGO-CZ, s.r.o.
Commercial Register maintained by the Regional Court in Hradec Králové
Section C, File 17879
Kladská 1082
500 03 Hradec Králové 3
Company ID: 25 96 39 61, VAT: CZ 25963961
Phone: 495 220 229, 495 220 394
Fax: 495 220 154
GSM gate: 602 123 096
E-mail: info@helago-cz.cz
Web: <http://www.helago-cz.cz>

MP1816 - Lower limb - superficial dissection
Order code: **4003.MP1816**





Cena bez DPH

3.722,00 Eur

Price with VAT

4.503,62 Eur

Parameters

Quantitative unit

ks

- Detailed description

This 3D printed specimen represents the remainder of the lower limb portions of our male abdominopelvic and proximal thigh specimen (MP1765), sectioned proximally near midthigh and continuous to the partially dissected foot. The transverse section through the thigh exposes the neurovascular structures of the anterior, medial and posterior compartments. This includes the great saphenous vein superficial to the terminal branches of the femoral nerve, femoral artery and vein in the anterior compartment, and perforating branches of the deep femoral artery in the medial and posterior compartments.

The remainder of the thigh, leg and dorsum of the foot have been dissected to demonstrate superficial structures and compartmental musculature, except the posterior aspect of the specimen which has been left undissected. The course of the great saphenous vein is displayed from the medial aspect of the thigh to the medial malleolus and the medial aspect of the dorsal venous plexus. The origin of the small saphenous vein from lateral branches of the dorsal venous plexus is also visible to the margin of the dissected superficial fascia near the lateral malleolus. The deeper femoral artery, vein and nerve branches are visible deep to the anterior compartment musculature (and a sectioned sartorius muscle) entering the adductor canal. Near the medial aspect of the knee joint the saphenous nerve is visible passing superficially near the great saphenous vein on the surface of the posterior crural fascia and terminating as the medial cutaneous nerve of the leg branches. On the lateral aspect of the leg the medial and intermediate dorsal cutaneous branches from the superficial fibular nerve are preserved passing onto the dorsum of the foot adjacent to the dorsal venous plexus tributaries.

Do you want to print the page now?

Hide some parts of page before printing



Print partially

Print the page as you see it now



Print complete page

(this box will not be printed)

Edit before printing

Hover your mouse over some part of page, a red rectangle will appear. Click it to hide the selected content of page.



Print!



Show hidden