



HELAGO-CZ, s.r.o.

Commercial Register maintained by the Regional Court in Hradec Králové

Section C, File 17879

Kladská 1082

500 03 Hradec Králové 3

Company ID: 25 96 39 61, VAT: CZ 25963961

Phone: 495 220 229, 495 220 394

Fax: 495 220 154

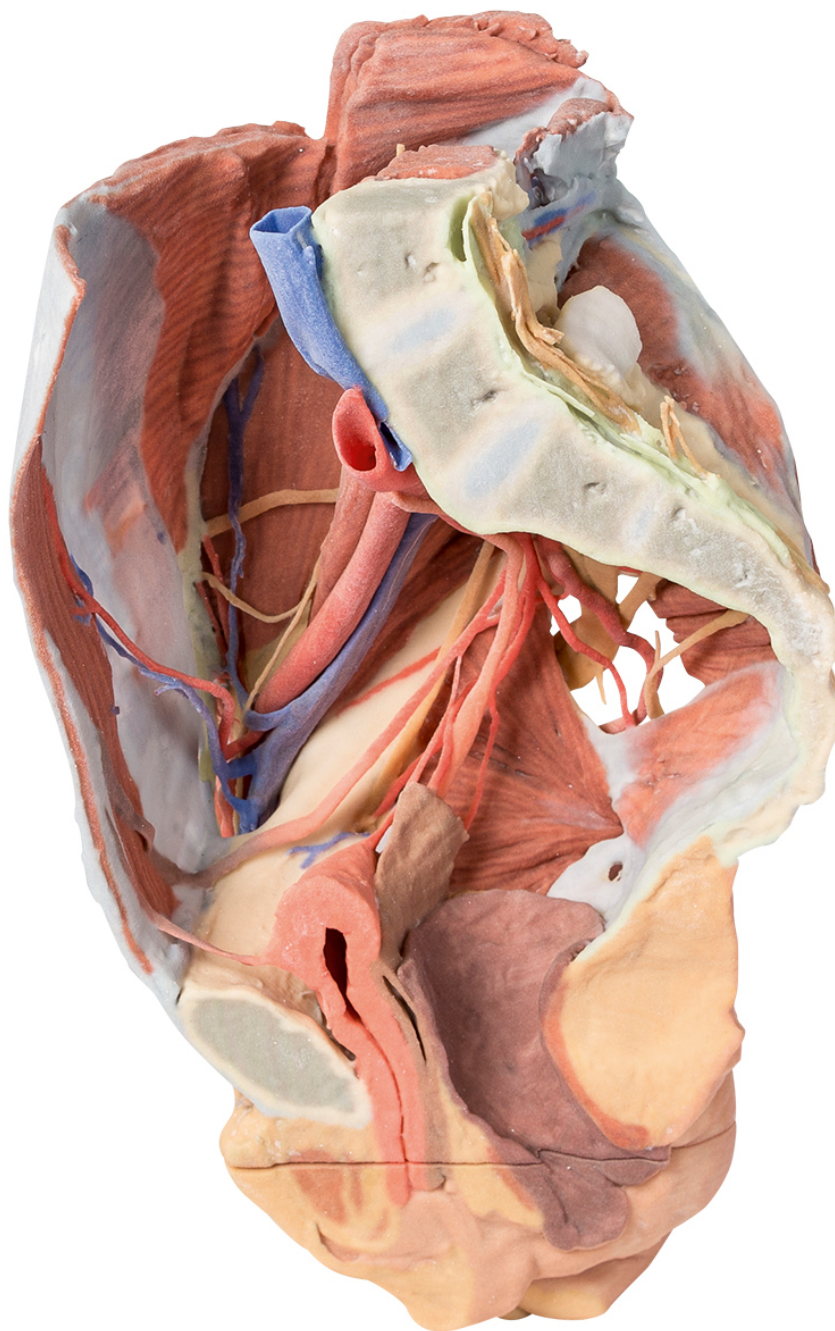
GSM gate: 602 123 096

E-mail: info@helago-cz.cz

Web: <http://www.helago-cz.cz>

MP1785 - Female right pelvis

Order code: **4003.MP1785**



Cena bez DPH

2.910,00 Eur

Price with VAT

3.521,10 Eur

Parameters

This 3D printed specimen represents a female right pelvis, sectioned along the midsagittal plane and transversely across the level of the L4 vertebrae and the proximal thigh. The specimen has been dissected to demonstrate the deep structures of the true and false pelvis, the inferior anterior abdominal wall and inguinal region, femoral triangle and gluteal region.

Internal anatomy

The muscular boundaries of the inferior abdominal cavity are defined posterolaterally by the quadratus lumborum, iliacus and psoas muscles; anteriorly by the (variably exposed) external and internal abdominal oblique muscles, the transversus abdominis and rectus abdominis. Inferiorly in the pelvic cavity, the obturator internus is visible traversing through the lesser sciatic foramen inferior to the sacrospinous ligament. Fibres of coccygeus merge with those of the sacrospinous ligament. Piriformis has been sectioned, with both origin visible within the cavity (and part visible in the gluteal region).

The common iliac artery arises from its cut edge at the level of L5, bifurcating at the level of the sacral promontory into the external and internal iliac arteries. The external iliac artery crosses the pelvic brim to give off the deep circumflex iliac artery and inferior epigastric artery before exiting the pelvis deep to the inguinal ligament. The internal iliac artery runs posterolaterally, giving the iliolumbar artery posteriorly and lateral sacral arteries which enter the anterior sacral foramina. A radicular artery entering the anterior foramina of the coccyx can also be seen. Inferiorly, the superior gluteal artery, inferior gluteal artery and internal pudendal artery exit the pelvic cavity through the greater sciatic foramen. A branch from the inferior gluteal artery, supplying psoas, travels anteriorly along the pectineal line.

Anteriorly, the umbilical artery gives off the superior vesical artery (supplying the bladder) before terminating against the anterior abdominal wall as the medial umbilical ligament. Posteriorly, the inferior vesical artery arises from the obturator artery before exiting the pelvis through the obturator canal. The uterine artery crosses over the ureter to enter the remnants of the broad ligament.

The major veins preserved are the inferior epigastric vein and deep circumflex iliac vein draining into the external iliac vein, and the iliolumbar vein and lateral sacral vein draining into the internal iliac vein. The external iliac vein and internal iliac vein unite to form the right common iliac vein which, at the level of L5, joins the (cut edge) of the left common iliac vein to become the inferior vena cava. Two veins pass horizontally across iliacus and quadratus lumborum.

Of the peripheral nerve structures preserved in this specimen, the lateral femoral cutaneous nerve passes laterally across the superficial aspect of the iliacus muscle and the femoral nerve is visible deep to the psoas major muscle. The genitofemoral nerve lies on the superficial surface of the psoas major, and the course of the genital branch entering the deep inguinal ring and the femoral branch passing deep to the inguinal ligament can be followed. The obturator nerve is also seen passing from deep to the psoas muscle anteriorly to the obturator foramen. In the true pelvis the lumbosacral trunk crosses the pelvic brim and joins the anterior ramus of S1. The S1-S3 anterior rami are visible and can be followed as they pass through the greater sciatic foramen and enter the gluteal region.

In addition to the muscular and neurovascular structures, parts of pelvic viscera have been preserved. Posterior to the pubic symphysis the median umbilical ligament extends superiorly from the bladder to the anterior abdominal wall. The ureter descends anteriorly to the psoas major muscle, across the iliac vessels, and beneath the uterine artery to enter the posterior bladder wall. The urethra is seen passing downwards to its opening at the urinary meatus, just posterior to the clitoris. Posterior to the bladder are the posthysterectomy remnants of the uterus at the apex of the closed, superior end of the vagina.

Posterior to this part of the cut rectum, anal canal and anus are present. Some muscular fibres of levator ani and the external anal sphincter can be seen in the ischioanal fossa just posteriorly to the anal canal.

External anatomy

In the posterior view, most of the multifidus and origin of the gluteus maximus have been removed over the lumbar and sacral region, and the laminae of L4 and L5 and the dorsal sacrum have been sectioned to reveal the cauda equina in the vertebral and sacral canal. The dura mater has been partially sectioned to expose the roots traversing the region, including the passage of the sacral ventral rami through the ventral foramina. Laterally, a large window into the gluteal maximus has been opened to expose the deeper structures of the gluteal region. Part of the sectioned piriformis is visible in the greater sciatic foramen, with the sciatic nerve (preserving an early division of the common peroneal and tibial nerves within the gluteal region) surrounded by the superior and inferior gluteal arteries. The sectioned internal pudendal artery and pudendal nerve rest on the sacrotuberous ligament as they descend towards the lesser sciatic foramen. Inferior to the sacrotuberous ligament the obturator internus muscle (along with the superior and inferior gemelli muscles) passes laterally deep to the common peroneal and tibial nerves. Inferior to these lateral rotators, the quadratus femoris and common origin of the hamstring group are visible just proximal to the remaining portion of the gluteus maximus.

In the anterior view, a window has been cut into the aponeurosis of the external oblique aponeurosis to reveal part of the transversus abdominis muscle. The inguinal ligament can be seen arising from the anterior superior iliac spine and extending towards the pubic tubercle. Inferior to the inguinal ligament, the fascia lata has been removed over the anterior thigh. The visible thigh muscles (from lateral

to medial) on this specimen include the tensor fasciae latae, and those of the anterior (sartorius, rectus femoris and the iliopsoas) and medial (gracilis, pectineus [sectioned], obturator externus, adductor brevis, adductor longus and adductor magnus). Between these muscle groups the femoral sheath has been removed to expose the contents of the femoral triangle (femoral artery and vein; sectioned to display the deeper adductor muscle fibers) and the femoral nerve that have entered this region deep to the inguinal ligament. In this individual the lateral circumflex femoral artery arises directly from the femoral artery. Inferior to this, the deep femoral artery (profunda femoris) branches off. Several anastomosing veins draining into the femoral vein surround the deep femoral artery. The femoral vein preserves an opening on the medial side corresponding to the drainage point of the great saphenous vein. The medial circumflex artery, posterior branch of the obturator nerve and a muscular artery can be seen passing just superficial to obturator externus. The anterior branch of the obturator nerve can be seen more anteriorly, passing superficial to adductor magnus and deep to adductor longus.

The sectioned thigh of the specimen allows for orientation of muscles and neurovascular structures in the proximal thigh. Other than the relations of anterior, medial and posterior thigh muscles, perforating arteries and veins are visible near the adductor magnus; and the common peroneal and tibial nerves are visible in the posterior compartment.