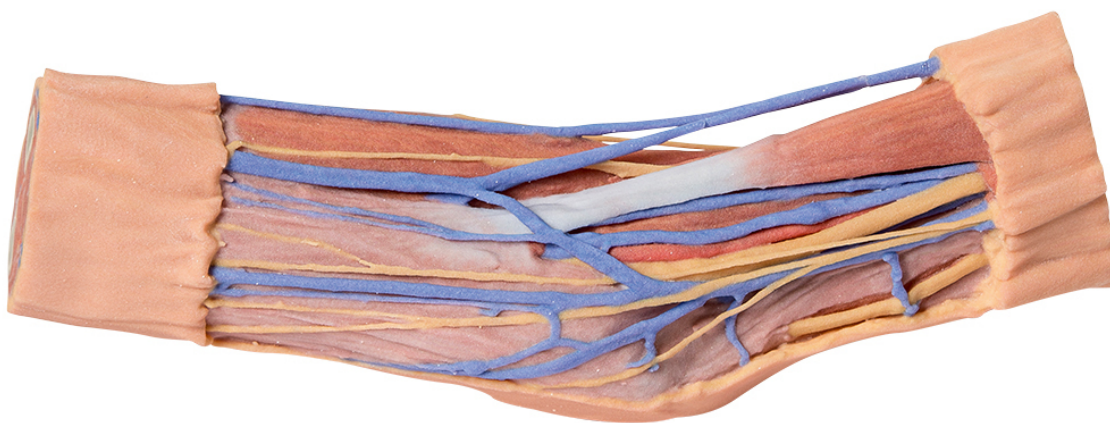


**MP1750 - Cubital Fossa**  
Order code: **4003.MP1750**



Cena bez DPH

687,00 Eur

Price with VAT

831,27 Eur

Parameters

Quantitative unit

ks

This 3D printed cubital fossa displays a superficial dissection of the right distal arm and proximal forearm. The skin and superficial fascia has been removed anteriorly, medially and laterally to expose the superficial veins (basilic, cephalic, and median cubital) and cutaneous (medial, lateral and posterior antebrachial) nerves. The deep fascia underlying these superficial structures has been largely removed, although the antebrachial fascia has been retained medially to demonstrate the merging of connective tissue fibers with the tendon of the biceps brachii through the bicipital aponeurosis. Medially, the ulnar artery is visible entering the cubital tunnel proximal to the medial epicondyle of the humerus. Anteriorly, the median nerve, brachial artery and accompanying veins in parallel to the biceps brachii. On the lateral aspect, the cephalic vein rests on the brachioradialis muscle, and the posterior antebrachial cutaneous nerve rests on the common origin of the forearm extensor muscles (and just anterior to the exposed origin of the triceps brachii muscle).

The proximal cross-section displays the anterior and posterior arm compartment muscles (biceps brachii, brachialis, triceps brachii), neurovascular bundles (median, ulnar, radial nerves; brachial artery and veins) and superficial veins (basilic, cephalic) visible at the midshaft of the humerus. The distal cross-section displays the anterior and posterior forearm compartment muscles separated by the interosseous membrane, as well as the superficial and deep neurovascular bundles (radial artery, vein and superficial branch of the radial

nerve; ulnar artery, vein and nerve; median nerve; anterior and posterior interosseous arteries, veins and nerves) and the distal continuations of the superficial veins and cutaneous nerves.